

HYALURONIC ACID THREADS FOR SKIN IMPROVEMENT

Alberto Diaspro, MD, MSc; Albina Kadjaya, MD; and George Sulamanidze, MD, PhD present the findings of their pilot split face study on the impact of HA threads on skin wrinkles

ABSTRACT

Background: stimulation of collagenesis, triggered by poly-L-lactic acid (PLLA), allows practitioners to enhance the long-lasting performance ensured by poly-caprolactone (PCA); however, it takes months to develop. Given the anti-ageing effect of hyaluronic acid (HA), it has now been embedded in PLLA-PCA threads, making it possible to achieve skin amelioration.

Objectives: this split-face pilot study highlights the differences between traditional and the new HA threads. It also aims at quantitatively assessing, using Quantificare Skin Analysis software (Quantificare S.A., Valbonne, France), wrinkles and skin texture on six subjects before, 1 and 3 months after thread insertion.

Methods: 5 threads were implanted in the right cheek, and 5 HA threads in the left cheek. Patients were checked for the following 30 and 90 days.

Results: HA threads show a better clinical outcome in skin micro-wrinkles. Skin texture appears to show the same outcome as normal threads.

Conclusions: the presented results point out the positive outcome of these new HA threads: a less inflamed post-insertion period and a unique tool that obtains a simultaneous lifting effect and skin rejuvenation. Further studies on larger patient groups are indeed needed to confirm these preliminary results.



ALBERTO DIASPRO M.D., M.SC., Maxillofacial Surgeon at the Rigenalab Centre for Regenerative Medicine, Turin, Italy; **ALBINA KADJAYA MD**, Dermatologist at Total Charm Clinic of Plastic and Aesthetic Surgery, Tbilisi, Georgia; **GEORGE SULAMANIDZE MD, PHD**, Plastic Surgeon at Total Charm Clinic of Plastic and Aesthetic Surgery, Tbilisi, Georgia

email: info@albertodiaspro.com

KEYWORDS

Hyaluronic acid, threads, skin quality, quantitative evaluation

THE FACIAL AGEING PROCESS RESULTS from a combination of skeletal and non-skeletal soft-tissue changes that lead to specific alterations of the superficial and deep fat framework and skin layers.

As the breakdown of collagen and elastic fibres takes place, noticeable weakening occurs in prominent facial regions such as cheeks, mandibular line and neck, and dermatochalasis of facial and neck soft tissue accounts for the distinctive signs of facial ageing¹.

The use of sub-dermal suspension with threads has gradually increased among many practitioners and attracted significant interest, given that it allows for the lifting of sagging tissue by means of a minimally invasive, closed procedure².

The shape, thickness and composite materials of threads may differ, depending on the preference of the practitioner and the needs of the patient.

It is generally stated that the placement of subcutaneous threads generates a non-specific local immune response to the implanted foreign material, which is known as a 'foreign body reaction' that lasts several months after the procedure and involves various cell types: the formation of a dense connective tissue capsule around the implanted material, chronic granulomatous inflammation, and fibrosis with neovascularization.

It is likely that this fibrotic response to implanted material plays an important buttress role in the ability of barbed suspension threads to lift facial tissues and maintain their elevated position in the long term. This fibrotic tissue and capsule formation ensures that the lifted tissues remain in place even after the thread has degraded. Therefore, it is possible to claim that the thread lifting effect is achieved and fortified by the cutaneous fibrotic reaction that appears along the thread itself and that remains steady even when the thread has been completely absorbed.

More precisely, once the threads are inserted into the skin, the formation of new collagen fibres and elastic fibres ensues, resulting in increased collagen and elastin volume. In addition, cells produce more hyaluronic acid in response to the threads with a concomitant increase in water retention. Collectively, this process results in visibly youthful skin.

The most commonly used threads are composed of bioresorbable materials such as poly-L-lactic acid (PLLA), polycaprolactone (PCL) or poly-dioxanone (PDO). Although the scientific literature contains numerous reports on the biocompatibility and host response to these compounds in both animals and humans, a systematic and comprehensive comparison of PLLA, PCL and PDO in terms of collagen and elastic fibres formation in these thread types is lacking. The authors would point out that, even if the market claims that the mentioned materials are effective to rejuvenate the skin, to date the histological demonstration of this phenomenon and moreover the comparison of the degree of skin rejuvenation induced by them has not yet been published.

“The use of sub-dermal suspension with threads has gradually increased among many practitioners and attracted significant interest, given that it allows for the lifting of sagging tissue by means of a minimally invasive, closed procedure.”

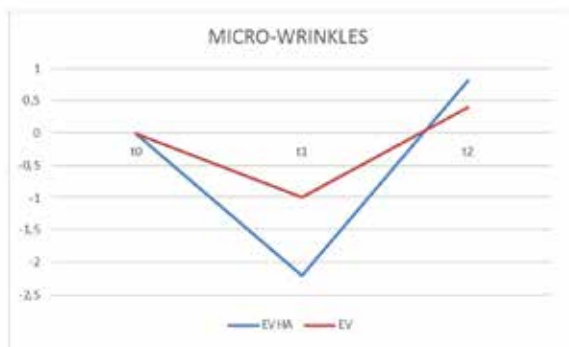


Figure 1 Normalized Skin Micro-wrinkle Outcome at t0 (prior), t1 (30 days) and t2 (90 days) after threads insertion. EVHA Excellence Visage Hyaluronic Acid, Aptos LLC, Tbilisi, Georgia. EV Excellence Visage, Aptos LLC, Tbilisi, Georgia

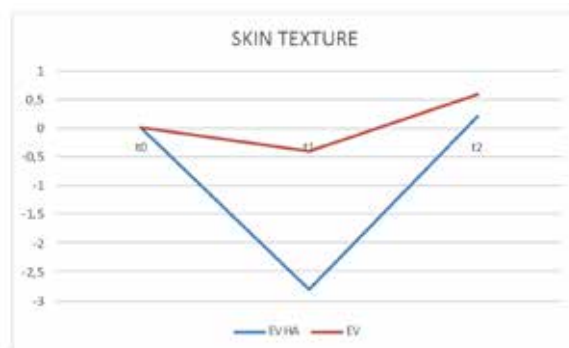


Figure 2 Normalized Skin Texture Outcome at t0 (prior), t1 (30 days) and t2 (90 days) after threads insertion. EVHA Excellence Visage Hyaluronic Acid, Aptos LLC, Tbilisi, Georgia. EV Excellence Visage, Aptos LLC, Tbilisi, Georgia

Recently, PLLA-PCA threads embedded with 1% of hyaluronic acid have been presented and animal studies already showed their unique characteristics compared to PLLA-PCA threads⁵: an inflammation-free HA-enriched thread encapsulation, a faster elastin increase after thread insertion, and a stronger elastin presence around the implanted HA-enriched thread providing for a better quality of the surrounding dermal tissue.

Collagen I production occurs earlier and in larger quantities up to the 60th day, without foreign body reaction, secondary to its breakdown, at the 90th day, with a shorter rehabilitation time. Clinical evaluation after thread insertion has already been provided⁶ and to the best of our knowledge a similar study on HA-PLLA-PCA threads has been published too⁷.

The authors present a pilot study based on quantitative evaluation of the aesthetic improvement of micro-wrinkles and skin texture in a split-face patient group which received implantation of HA-PLLA-PCA threads in the right and PLLA-PCA threads in the left cheek. The evaluation was carried out by means of LifeViz Mini (Quantificare S.A., Valbonne, France) and its Quantificare Skin Analysis software.

Materials and methods

Between December 2018 and April 2019, 6 patients were enrolled in this study, 3 women and 3 men.

Men were aged between 41 and 49 years (mean age 45.3 years), while women were between 54 and 68 years (mean age 64.5 years).

The assessment focused on:

- Skin micro-wrinkles
- Skin texture (compactness and homogeneity) prior to, 30, and 90 days after threads insertion.

Participants were asked to maintain the same skin care regimen throughout the study and 4 weeks prior to baseline, as well as adhere to study procedures while attending all sessions within the timeline of the study.

The study protocol followed the ethical guidelines of the Declaration of Helsinki and the participants were asked to give their informed consent prior to any study procedure. All patients consented to the reproduction of recognizable photographs.

Exclusion criteria included any treatment one year prior to baseline and in the following 6 months, including:

- Facial soft-tissue fillers
- Laser
- Energy-based devices application on the face or neck
- Treatment with isotretinoin or oral acne medications
- Botulinum toxin A injections in the face or neck.

The enrolled participants were treated with poly-L-lactic poly-caprolactone PLLA-PCA and hyaluronic acid HA-PLLA-PCA suspension threads (Excellence Visage-EV and Excellence Visage EVHA, Aptos LLC, Tbilisi, Georgia) to correct mild to moderate ptosis of the flabby tissues of the midface.

Local anaesthesia of the skin has been performed with a solution of lidocaine 2% with epinephrine 1:100000 and, after a 15 minutes waiting time for proper vasoconstriction of the superficial vessels of the face, threads pre-loaded on a blunt cannula were inserted from the zygomatic arch and the pre-tragus point, to the nasolabial fold and marionette line.

Excellence Visage with hyaluronic acid (EVHA) threads were implanted in the right and Excellence Visage (EV) threads in the left cheek, in order to later assess skin quality improvement and compare both sides.

Patient photographs were taken using LifeViz Mini (Quantificare S.A., Valbonne, France) and its Quantificare Skin Analysis software before (t0), 30 (t1) and 90 (t2) days after threads implantation. This tool allows practitioners to assess skin micro-rhytides as a combination of depth, length, and width of the main wrinkles, as well as skin texture as a global measurement of the skin surface's roughness in the region of interest.

Every parameter is evaluated by the software with respect to scores which are provided on a scale between -10 and +10, representing the standard deviation relative to a matching population with respect to age, gender, and skin type (Fitzpatrick scale) where +10 translates to excellent skin condition (no wrinkles, smooth skin) and -10 translates to poor skin condition (many deep wrinkles, rough skin).

Results

Five out of the six patients completed the study with one

drop-off during the follow-up period, that was 84 days (from 63 to 91 days).

Three months after the insertion, HA-PLLA-PCA threads show a better clinical outcome in skin micro-wrinkles (*Figure 1*), while skin texture appears to show the same outcome as PLLA-PCA threads (*Figure 2*).

HA-PLLA-PCA threads present with an inverse peak of clinical action recorded thirty days after implantation (t1) for both investigated parameters, before reaching final improvement at t3, that points out the inverse correlation between dynamics of connective tissue around HA-threads and clinical findings, as discussed later.

No adverse events were reported during thread insertion or later, except for a slight aching sensation at the insertion points.

Patient discomfort was referred to be mild, mainly related to thread perception and presented with spontaneous resolution in all treated cases.

Discussion

This pilot study has been designed and carried out with the common assumption that results from cosmetic procedures are very subjective, yet there needs to be a method for determining the true outcome of treatments besides the mere judgement of patients and clinicians.

Digital photography and its related skin analysis software provided by Quantificare S.A., Valbonne, France has been chosen as the method to overcome this and therefore standardized photos of the results of this study are presented, along with analytic data evaluation. (*Figure 3*, *Figure 4*).

The inverse peak of clinical effect at t1 that HA-PLLA-PCA threads show, before coming to a final improvement at t2, points out the inverse correlation between the dynamics of connective tissue around HA-threads and clinical findings.

The more inflamed tissue around normal PLLA-PCA threads once inserted, lead to more swollen and tightened skin, as recorded in the first period (t0-t1), which mimics fewer micro-rhytides and a better texture.

HA hydration and its anti-inflammatory properties provide for a more physiological tissue condition around the implanted thread, presenting with a less relevant clinical improvement (t1), eventually ending up with the great effect on micro-wrinkles (t2).

This is indirectly confirmed by the elastin synthesis curve, that without the inverse peak, directly correlates with the final good outcome of the clinical data, pointing out that skin with implanted HA enriched threads presents with unaltered physiological features in the first post-treatment period and later improves, overcoming the normal thread outcome in micro-rugosity.

The presented results confirm the previously published⁸ histological findings, highlighting the innovative aspect and the clinically positive outcome of this new HA-PLLA-PCA thread: a less inflamed post-insertion period and a unique tool to obtain simultaneous lifting effect⁸ and skin rejuvenation for a patient with mild to moderate ptosis of the facial tissues.

We recorded no side-effects or complications related

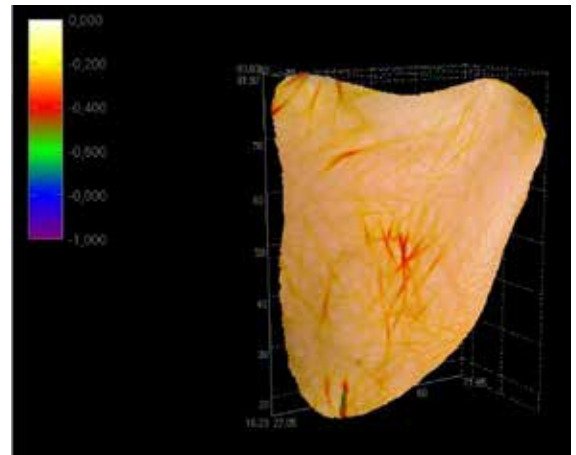


Figure 3 Tridimensional wrinkles evaluation before threads insertion, performed by LifeViz Mini[®] Skin Analysis software (Quantificare S.A., Valbonne, France)

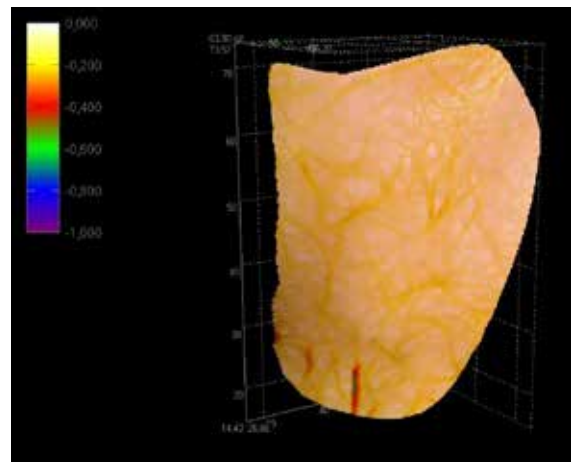


Figure 4 Tridimensional wrinkles evaluation three months after threads insertion, performed by LifeViz Mini[®] Skin Analysis software (Quantificare S.A., Valbonne, France)

to thread insertion, its lifting action, and the embedded hyaluronic acid rejuvenating action. This demonstrates that the operative protocol is safe and its results are reliable.

These results showed that with threads, it is now possible to achieve a combined skin rejuvenation effect coupled with tissue suspension.

To the best of our knowledge, this is the first objective, standardized photographic analysis of facial skin rejuvenation obtained by means of thread insertion, along with the results published by Poleva P,⁷ both carried out to overcome the subjectivity of cosmetic procedure assessment in evaluating immediate and three-months post-implantation results.

Further studies on larger patient groups are indeed needed to confirm the preliminary results shown in the present study.

Conclusions

The results of this pilot study suggest that new hyaluronic

acid-enriched poly-L-lactic acid/poly-caprolactone threads insertion is a safe and effective method to treat skin flaws affecting not only facial tissues ptosis but also texture and micro-rhytides.

Because of the high satisfaction rate both among the authors and treated patients, and the presented preliminary results, we can state that it is now possible to reach a skin rejuvenating effect coupled with tissue reposition through the use of resorbable threads.

Longer follow-up and a larger number of patients are needed in order to corroborate the results and the related statements of this pilot study.

► **Declaration of interest** *Dr. Diaspro is a consultant for Aptos LLC, Dr. Kadjaya is a consultant for Aptos LLC, Dr. Sulamanidze is owner of Aptos LLC*

► **Figures 1-4** © Dr Diaspro



Key points

- ❗ Hyaluronic acid hydration and its anti-inflammatory properties provide for a more physiological tissue condition around the implanted thread
- ❗ PLLA-PCA threads embedded with 1% of hyaluronic acid have shown to trigger an inflammation-free encapsulation, a faster elastin increase after their insertion, and a stronger elastin presence around the implanted thread, providing for a better quality of the surrounding dermal tissue
- ❗ Hyaluronic acid-enriched poly-L-lactic acid/poly-caprolactone threads insertion is a safe and effective method to treat skin flaws affecting not only facial tissues ptosis, but also texture and micro-rhytides

References

1. Sulamanidze M et al. Avoiding Complications with Aptos Sutures. *Aesthet Surg J*. 2011 Nov;31(8):863-73
2. Gülbitti HA et al. Thread-Lift Sutures: Still in the Lift? A Systematic Review of the Literature. *Plast Reconstr Surg*. 2018 Mar;141(3):341e-347e
3. CG Lee et al. Histological Evaluation of Bioresorbable Threads in Rats. *Korean J Clin Lab Sci*. 2018;50(3):217-224
4. Sulamanidze GM et al. The Subcutaneous Tissue Reaction on Poly (L-lactide-co-caprolactone) based Threads. *Int J Clin Expl Dermatol*, 2018 Vol.3 Issue 2
5. Nikishin DV et al. Effectiveness of using Poly Lactide and Caprolactone Acid with Hyaluronic Acid Material. *Adv Plast Reconstr Surg*, 2019;3(2): 274-284.
6. Lukyanchenko E. Evaluation of the effectiveness and safety of absorbable threads, made of polylactic acid in combination with caprolactone, in age-related changes of the skin. *International Journal of Aesthetic and Anti-Ageing Medicine*, 2018
7. Poleva I, Albina K. Single-blind Comparative Study of the Aesthetic Outcome of Armouring Procedures with PLLA/PCL and Ha-enriched Absorbable Threads *Cosmetol Open J*. 2019; 1(2): 15-20
8. Sulamanidze M, Sulamanidze G. Aptos suture lifting methods: 10 years of experience. *Clin Plast Surg*. 2009 Apr;36(2):281-306